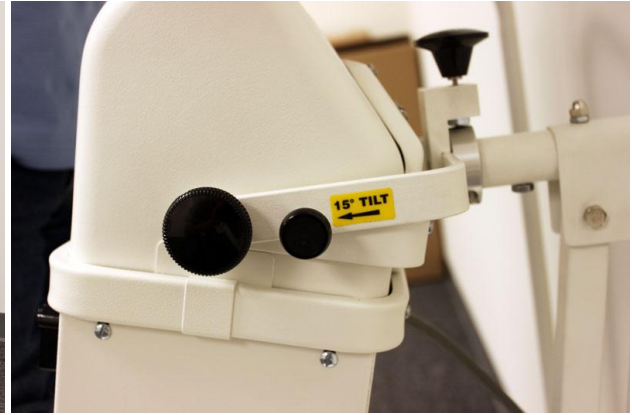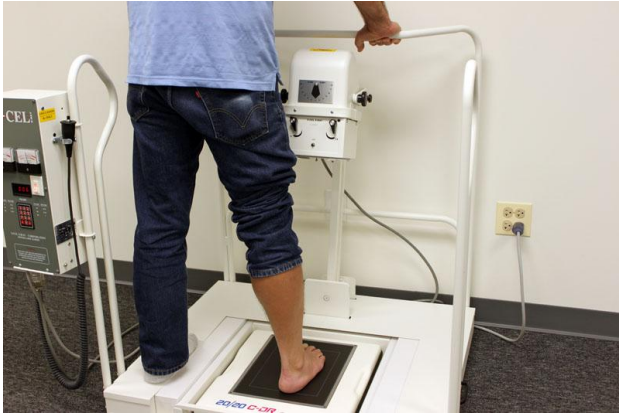

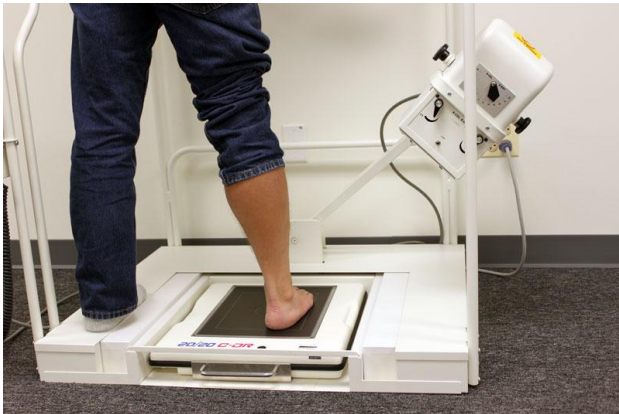
PODIATRY X-RAY VIEWS

<- Foot AP/PA ->



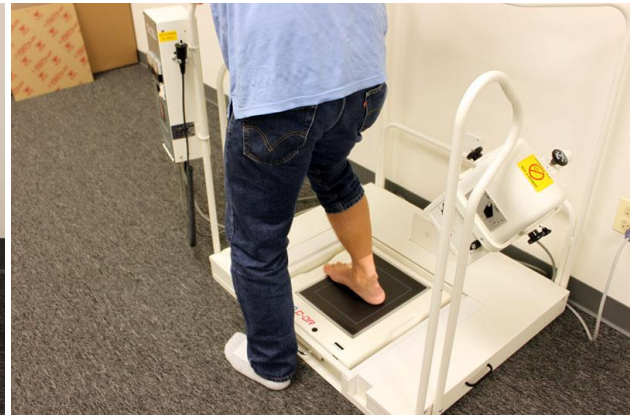<- Foot Oblique ->



Ankle AP/PA



Calcaneal Axial



<- Foot Lateral ->

